

What to do with Chronic Feline Upper Respiratory Infections (URI)?

Feline Upper Respiratory Infections (URI) is a collective term for infectious diseases of the upper respiratory tract and the mucous membranes of cats. It thus is a complex of symptoms, caused by different pathogens, affecting nasal and oral cavities and the eyes. Pathogens are different viruses as well as bacteria and fungi.

Since most of these pathogens benefit each other and can therefore occur parallel and as the therapy against these diseases has several similarities, the collective term URI is still entitled. It should, however, always be clarified if foreign bodies (e.g. swallowed blades of grass), feline asthma or allergies as well as a tumors come into consideration.

Therefore feline respiratory diseases are always multifactorial events.

Feline URI symptoms are complex and can therefore not be assigned to a specific pathogen. They range from a mild, only watery, nasal defluxion to terminal general diseases. It comes to sneezing and conjunctivitis, lesions in the oral cavity, fever and pneumonia.

Owners report on hoarseness or noises when the cat is inhaling (most likely an involvement of the upper respiratory passages) or exhaling (most likely an involvement of the lower respiratory passages).

Often a viral infection is the trigger of this "vicious circle", causing lesions, swelling of the mucous membrane and promoting inflammatory mediators. The nasal concha surface gets affected and bacterial secondary infections are supported.

For the most part there firstly are viral infections. Most common viral pathogens are, besides unspecific *Adeno-*, *Rhino-* or *Pneumo viruses*, the **Feline Herpes virus (FHV)** and the **Feline Calici virus (FCV)**.

Feline Herpes viruses (FHV) have a low environmental stability. This means that they are solid in their genetic variation and therefore much easier to detect by molecular diagnostics (PCR) than *Calici viruses*. In FHV, respiratory symptoms like sneezing and sinus infections with ocular and nasal defluxion are predominant. Conjunctivitis and corneal ulcers often occur. The cats suffer from respiratory distress/dyspnoea and anorexia. Usually, these symptoms fade away relatively quickly.

However, the FHV infected cat remains a lifelong virus carrier and the latent infection can be re-activated under stress at any time. Complications following FHV infections are rare, although sometimes the ocular alterations are so severe that the cat may go blind. The disease can even be fatal in very young kittens due to very high fever and general weakness (Fading Kitten Syndrome).

Feline Calici viruses (FCV) consist of many strains what leads to a vast genetic variety. In practice this means that even vaccinated cats can come in touch with viruses against which they have only insufficient or no immunity at all. Due to virulence differences, clinical symptoms can range from anorexia and fever to joint and muscle pain or, less often, pneumonia. The ulcers commonly seen in the oral cavity and gingiva are often worsened by bacterial co-infections.

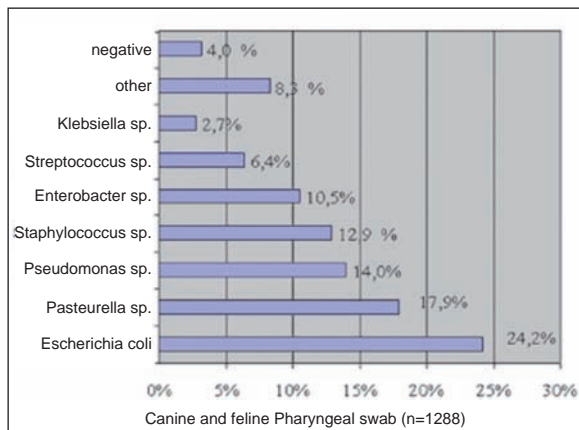


Fig. 1: Bacteriology in pharyngeal swabs of cats and dogs

A list of bacterial and mycological infections found in 1288 pharyngeal swabs can be seen in Fig. 1. Of these were only 4 % negative. And of 269 swabs submitted for mycological examination positives were found in 23.2 % of canine and 8.1 % of feline samples. Yeasts, like *Candida* spp., are not often found in cats (1% positives) compared to dogs (12.2% positives) (Fig. 2).

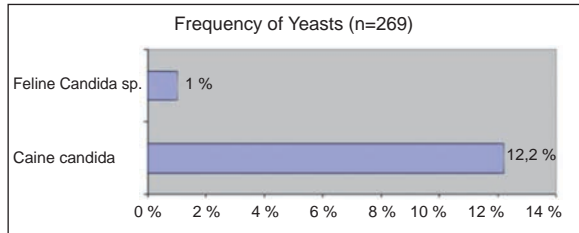


Fig. 2: *Candida* spp. in pharyngeal swabs of dogs and cats

Further pathogens causing Feline URI are *Chlamydomphila felis*, *Mycoplasma felis* and *Bartonella henselae*.

Chlamydomphila felis is obligate intracellular and cannot multiply without enzyme activity of a correspondent host cell. It is frequently found in connection with feline conjunctivitis. *Chlamydomphila felis* goes through an intracellular and an extracellular phase during its propagation. During the infectious extracellular phase it can only survive a few days at room temperature, but can survive up to one month at 4°C. Most likely

various *Chlamydomphila felis* variants exist with variable virulence. Transmission is by direct contact and symptoms can persist for several weeks in some animals.

Mycoplasma felis is very unstable outside the organism and is mostly found on the mucous membranes of the respiratory, urinary and genital tract where they can escape the immune reaction of the infected animal for a long time. Less frequently *Mycoplasma felis* causes diseases in the upper airways. Clinical symptoms are conjunctivitis and sneezing. The infection generally heals spontaneously after two to four weeks. It is still not known whether *Mycoplasma* is a primary or just a secondary pathogen. Pathogens like *Mycoplasma gatae* and *Mycoplasma feliminutum* are sometimes isolated from cats as well, but their clinical importance is questionable. ***Bartonella*** are intracellular bacteria, vector-borne transmitted through fleas and ticks. They cause "Cat Scratch Disease" in humans with pustules and oedema and in severe cases generalized lymphadenopathy. Feline *Bartonella* infections are mostly subclinical, but fever, muscle pain, localized lymphadenopathy and, seldom, neurologic symptoms can emerge, lasting only a few days, seldom weeks. *Bartonella henselae* as part of the feline oral mucous membrane infection is currently being discussed.

Bordetella bronchiseptica is commonly seen in dogs causing "Kennel cough", but feline *Bordetella bronchiseptica* infections are more seldom. Symptoms are mild and they disappear spontaneously after about 10 days. In young kittens, however, fatal pneumonia can develop. *Bordetella* normally does not survive for a long time outside the host. The transmission happens through direct contact or aerosols.

Diagnostically bacteria can be isolated from a standard pharyngeal or eye swab (with medium). Susceptibility testing should be performed for appropriate therapy and this will also allow treatment of possible concurrent infections.

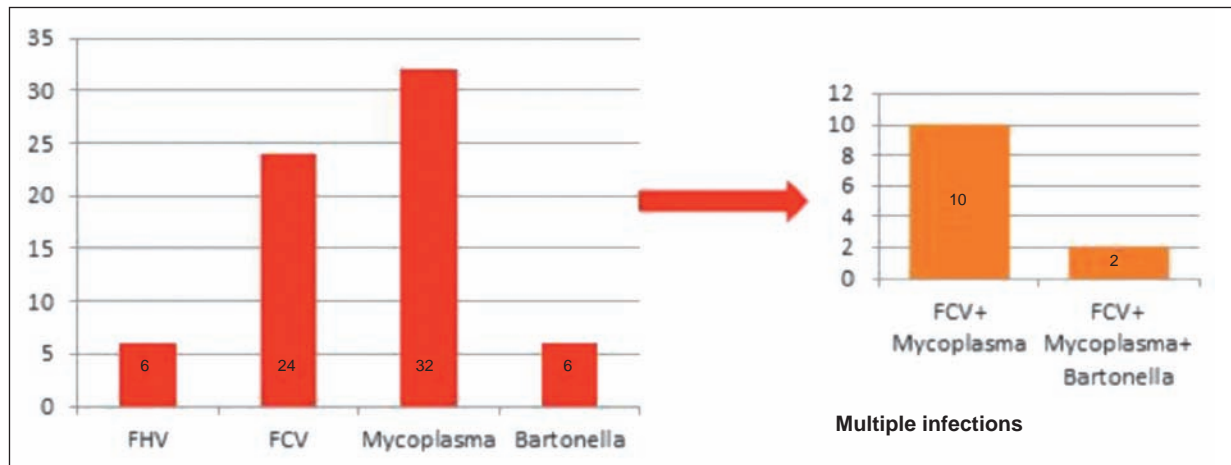


Fig. 3: Results of feline pharyngeal swabs, n=68

Viral infections as well as *Chlamydomphila* and *Mycoplasma* are diagnosed using Polymerase Chain Reaction (PCR). Thereby a conjunctiva or pharynx smear should be taken with a dry swab or cyto-brush which can then be sent in without a medium. Before sampling, any mucus or pus should be removed from the affected spot and the area should be thoroughly swabbed to get enough cells on the swab.

In **practice** those results mean a great advantage, especially in regard to the therapy. It is important to determine how far a single or multiple infection exists.

In **catteries or animal shelters** with up to 40% of clinically conspicuous cats a high prevalence of non-clinical carriers can be assumed.

Treatment of feline upper respiratory infections (URI) requires intensive care, good hygiene and clean, warm and well ventilated surroundings. Beside the local eye therapy with antibiotics (e.g. Tetracycline or Gentamycin administrated daily as often as possible over at least three weeks), in case of infections with *Chlamydomphila*, *Mycoplasma* and *Bordetella* a systematic antibiotic treatment is required.

Doxycyclin	5mg/kg	BID
Enrofloxazin	5mg/kg	SID
Azithromycin	10-15mg/kg	3 days SID + 4 weeks twice weekly
Amoxicillin/Clavulansäure	12.5mg/kg	BID for 4 weeks

* See remarks at the end of the text

Unfortunately, no pathogen elimination is achieved with Azithromycin and Amoxicillin/Clavulanic acid treatment.

Antiviral treatment is, due to the many side effects and relatively high costs, more difficult.

FHV can be treated with Ganciclovir eye drops, or systemically with Famciclovir (¼ 125mg tablet/5 kg cat, 1-2 times daily). The active ingredients Acyclovir or Ribavirin must not be used in cats.

Lysine orally (500mg/cat/BID) has also proven to be effective in treating viral infections. It reduces the bioavailability of Arginine and represses the viral replication. Relapses occur less severely.

Mostly the use of human or feline interferon has not the desired effect. Diluted solutions can, however, be administered orally or as eye drops. Here positive cases are described.

In cats with a concurrent allergic component, antihistamines like Loratidine can be used.

Important is good accompanying care, cleaning of eyes and nose, sufficient fluid therapy, and, if applicable, the dispensation of Cyproheptadine (0.5mg/kg/BID) or Diazepam (0.5mg/kg/i.v.) to increase appetite. In case of pain due to stomatitis and gingivitis NSAID can be given.

The use of expectorants and inhalation therapy is also effective in some cases. The cat can be placed in a pet carrier with a vaporizer placed under a blanket.

Pseudoephedrine (1mg/kg) can also be used as well as nose spray for children to free the airways.

Prophylactic vaccinations against FHV and FCV have been routine for years. However or precisely because the cat population in Germany is increasing more and more, there can be no talk of comprehensive vaccination coverage.

A vaccination against FHV surely provides a good immunity, but it cannot prevent the development of a prevailing carrier state. An immunization against FCV is very difficult due to the vast strain variance. FCV vaccines do unfortunately not offer complete protection against new or more aggressive variations.

Yet it is recommended to vaccinate cats suffering from URI if their clinical picture allows a vaccination.

A vaccination against *Chlamydomphila* and *Bordetella* has been available for several years now, but is not used routinely.

**Treatment proposal according to Eule/Fu Berlin and Scherk, JFMS, vol. 12, 7, 2010.*